



Distal Convoluted Tubule

Proximal Convoluted Tubule

Bowman's Capule

Glomerulus

Peritubular Capillaries

Loop of Henle

Descending Limb

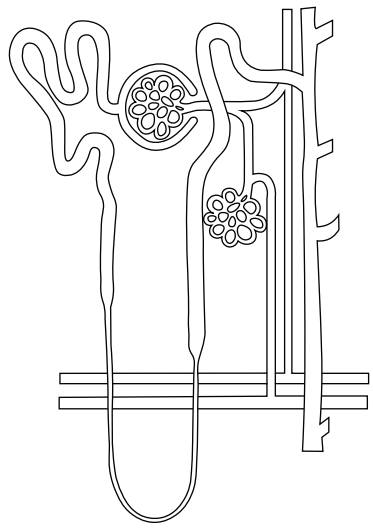
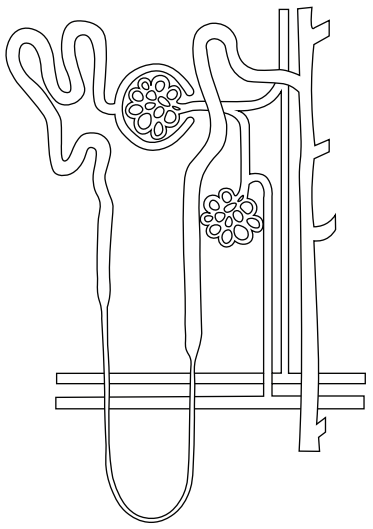
Ascending Limb

Branch of Renal Artery

Branch of Renal Vein

Efferent Arteriole

Afferent Arteriole



Collecting Duct

Renal Pelvis