



Renal Cortex

Renal Medulla (Pyramid)

Renal Vein

Renal Artery

Renal Pelvis

Ureter

Fibrous Capsule

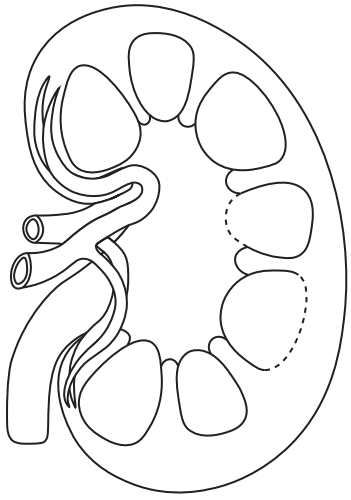
Renal Lobe

Minor Calyx

Major Calyx

Renal Column

Renal Papilla



Corticomedullary Junction