



Manubrium

Xiphoid Process

Clavicular Notch

Jugular Notch

Body

Cervical Vertebra

Thoracic Vertebra

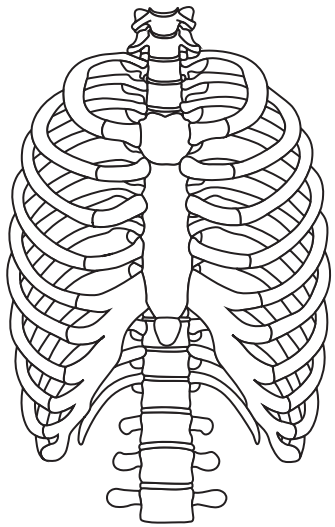
Lumbar Vertebra

Costal Cartilage

True Ribs (1-7)

False Ribs (8-10)

Floating Ribs (11-12)



Sternal Angle