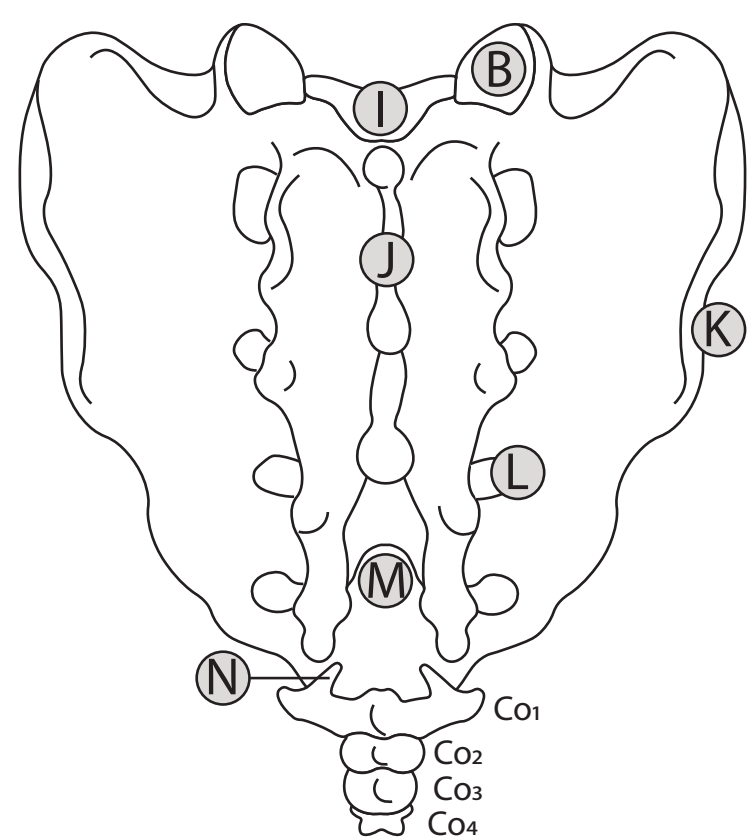
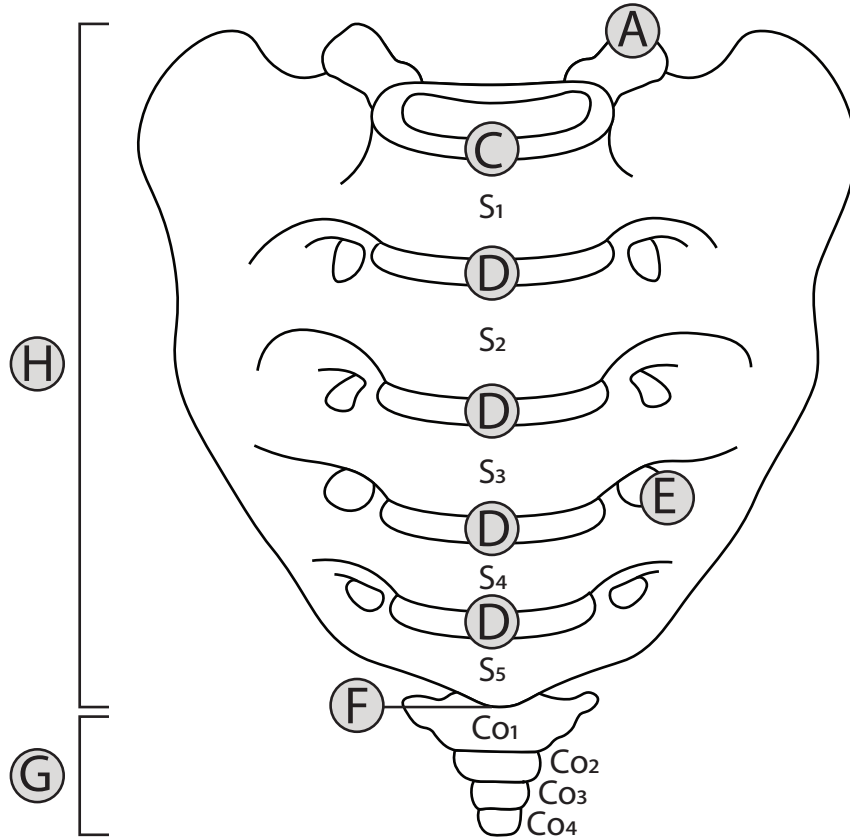


Anterior View

Posterior View



- | | | | |
|----------|----------------------------|----------|---------------------------|
| A | Superior Articular Process | B | Superior Articular Facet |
| C | Promontory | D | Transverse Ridges |
| E | Anterior Sacral Foramina | F | Apex |
| G | Coccyx | H | Sacrum |
| I | Sacral Canal | J | Median Sacral Crest |
| K | Articular Surface | L | Posterior Sacral Foramina |
| M | Sacral Hiatus | N | Coccygeal Cornu |