



Frontal Bone

Parietal Bone

Temporal Bone

Sphenoid Bone

Ethmoid Bone

Lacrimal Bone

Nasal Bone

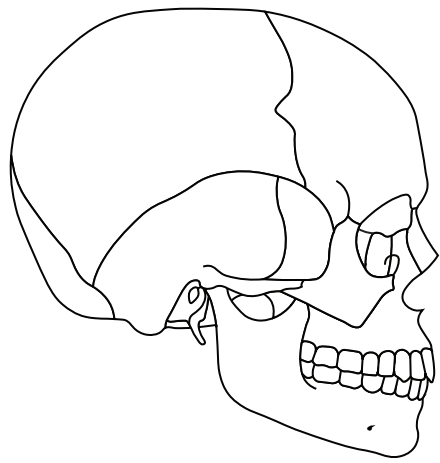
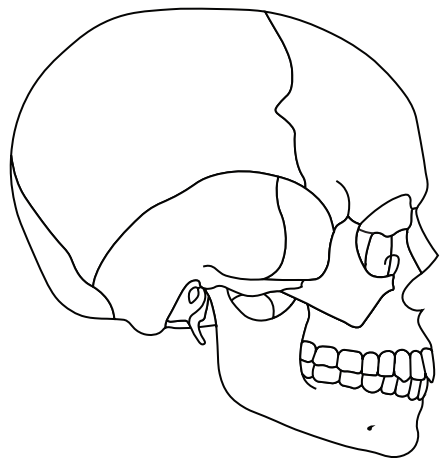
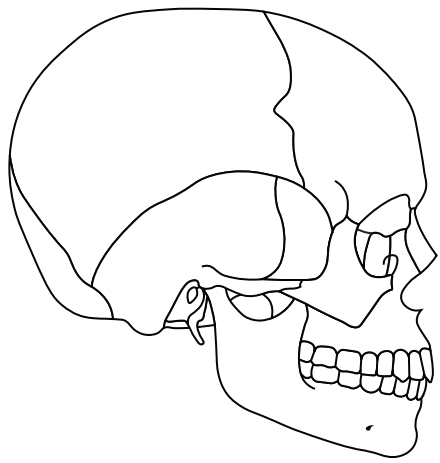
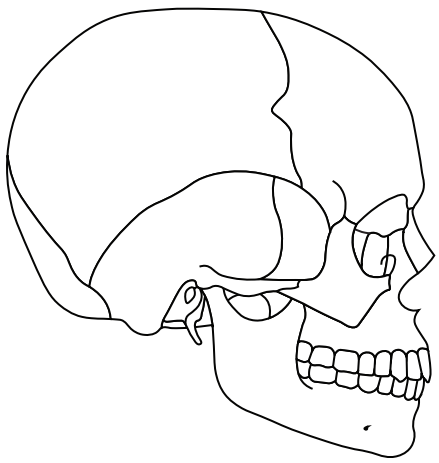
Zygomatic Bone

Mandible

Maxilla

Occipital Bone

External Acoustic Meatus



Styloid Process

Lambdoid Suture

Squamous Suture

Coronal Suture