



Head

Neck

Shaft

Fovea

Greater Trochanter

Lesser Trochanter

Intertrochanteric Line

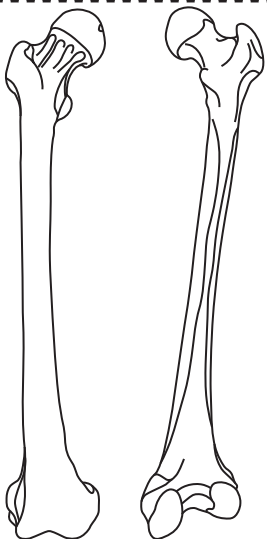
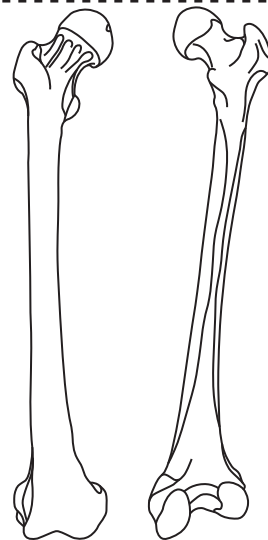
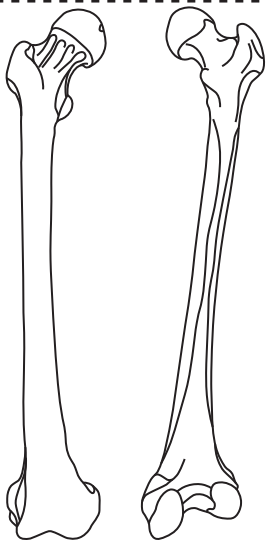
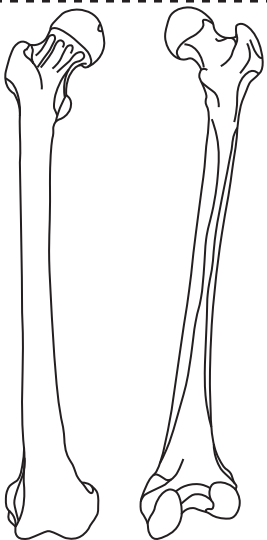
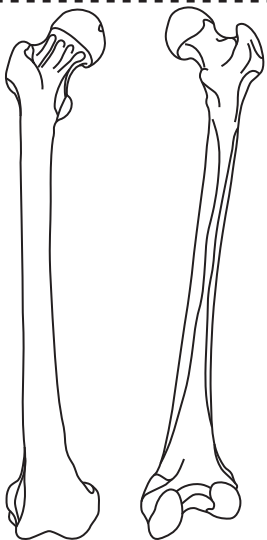
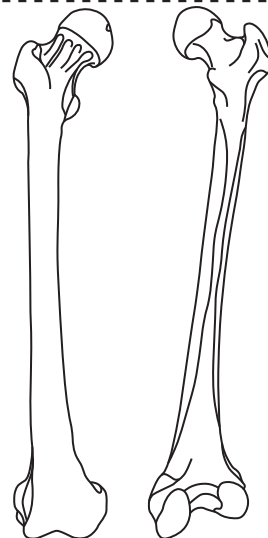
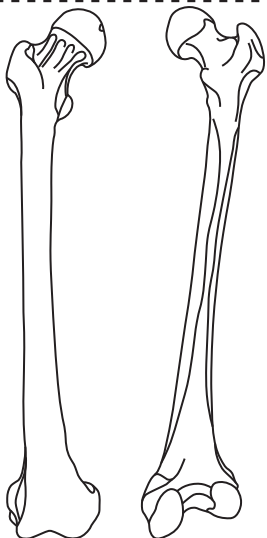
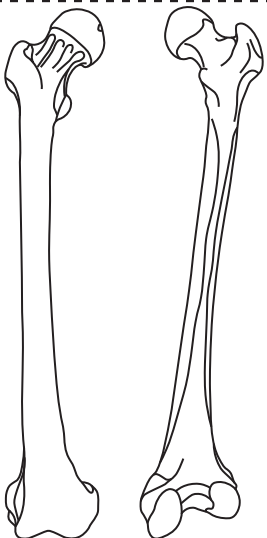
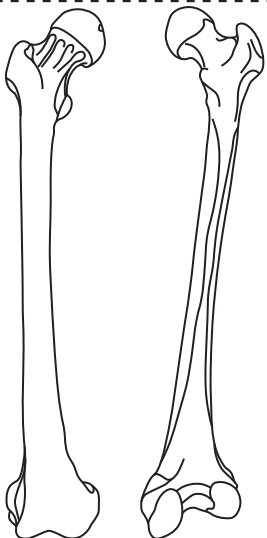
Intertrochanteric Crest

Pectineal Line

Gluteal Tuberosity

Linea Aspera

Intercondylar Fossa



Medial Supracondylar Line

Lateral Supracondyle Line

Medial Epicondyle

Lateral Epicondyle

Medial Condyle

Lateral Condyle

Adductor Tubercle

Popliteal Surface

Patellar Surface