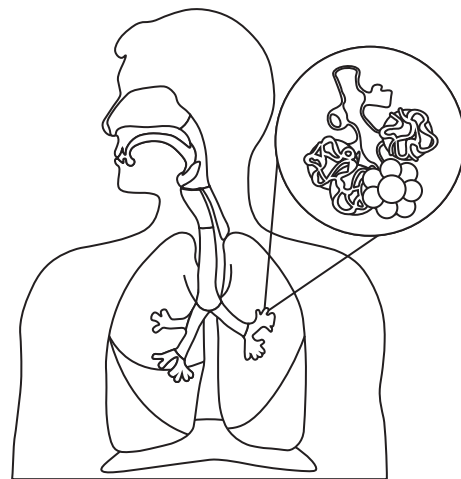
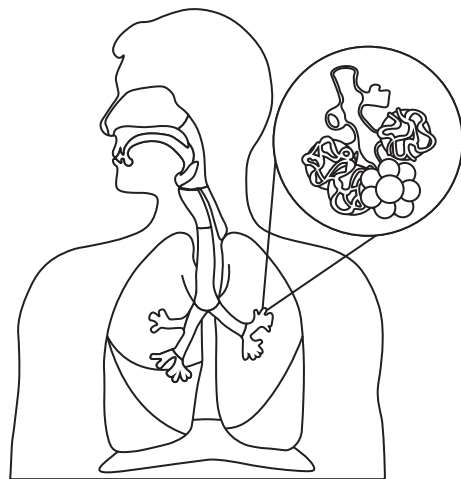
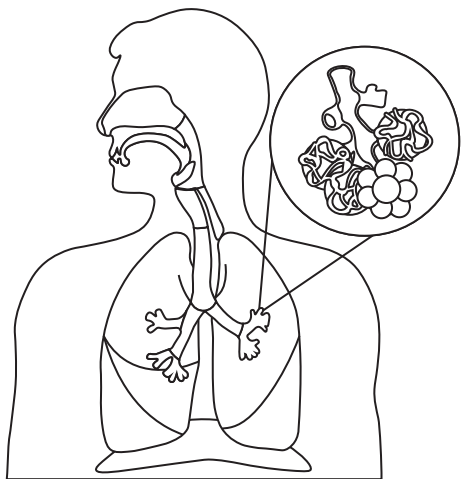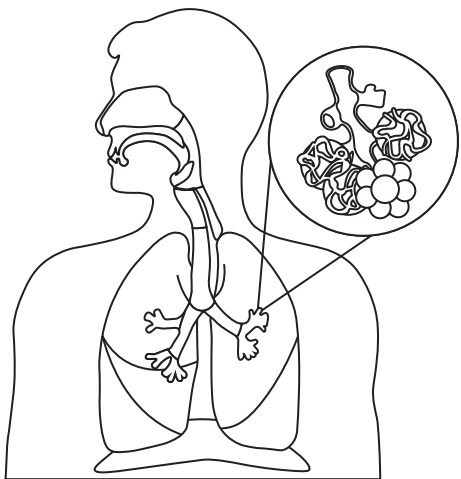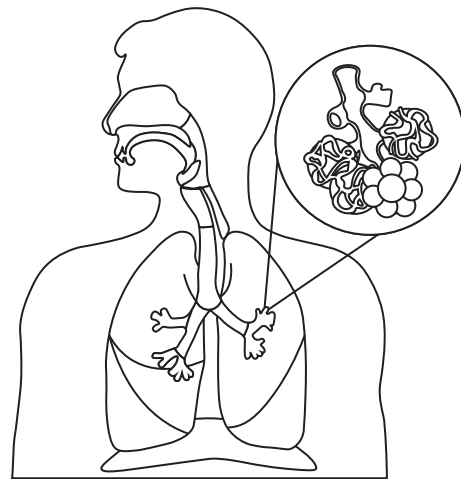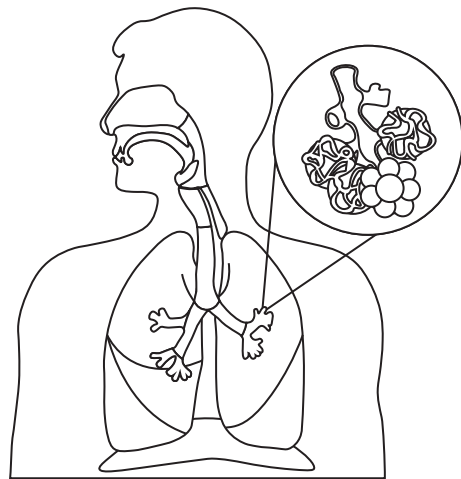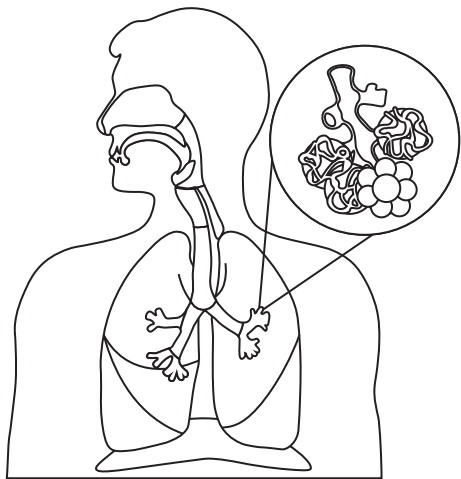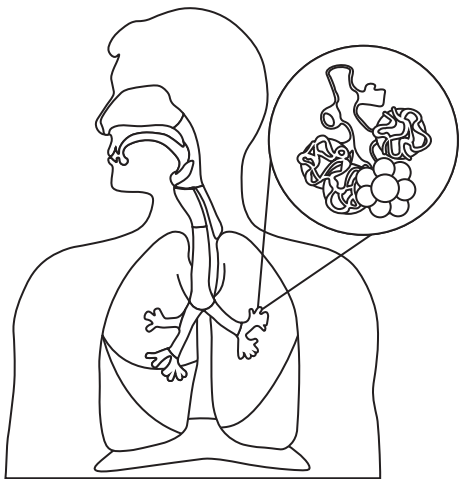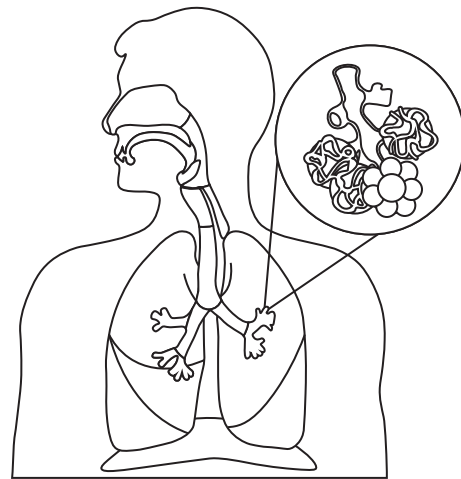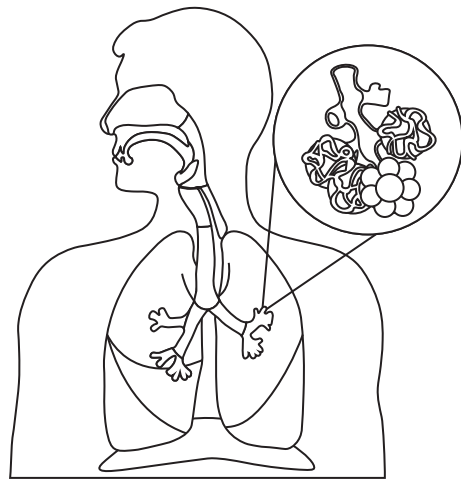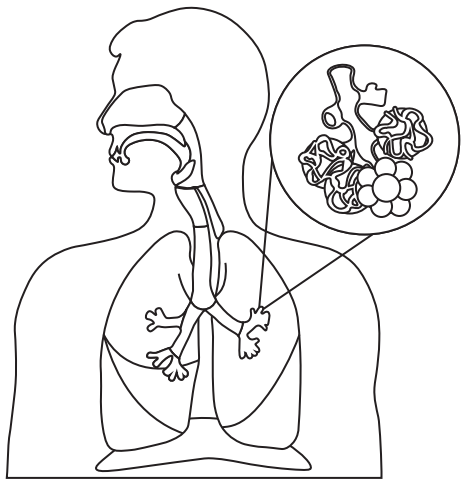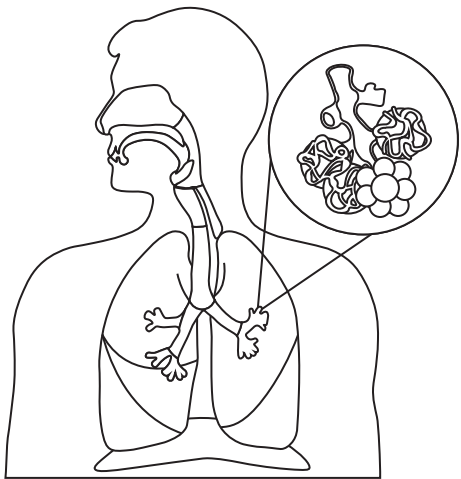Nasal Cavity

Pharynx

Trachea

Secondary Bronchus

Oral Cavity

Larynx

Primary Bronchus

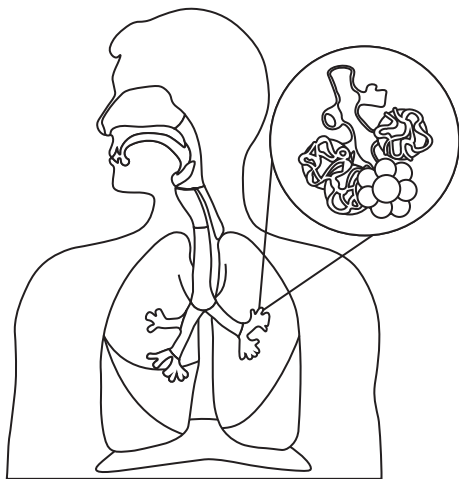
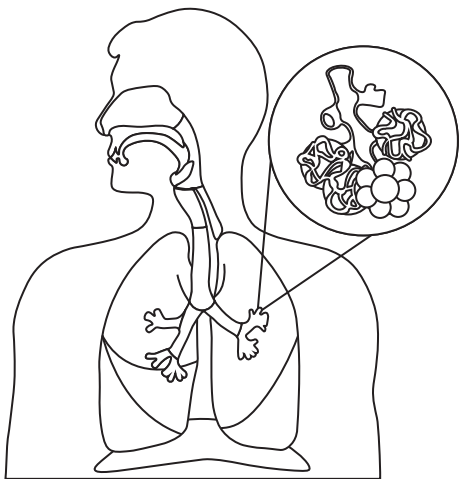
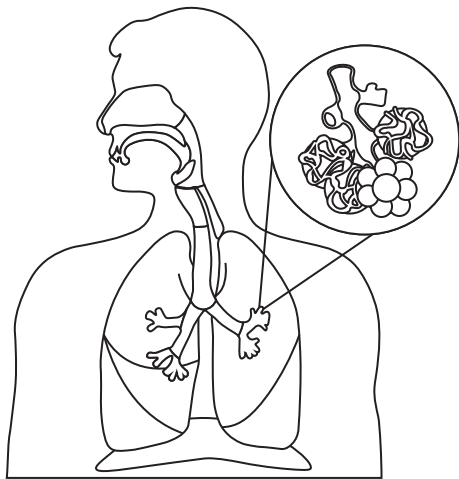
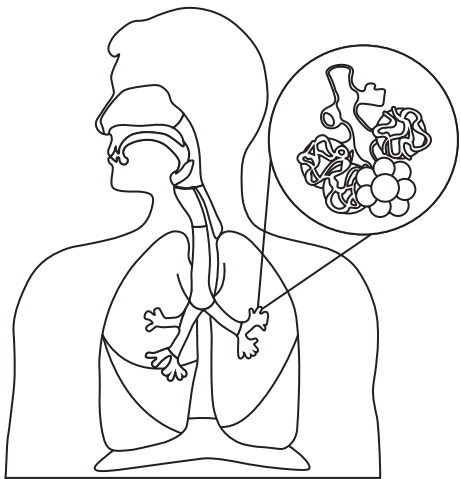
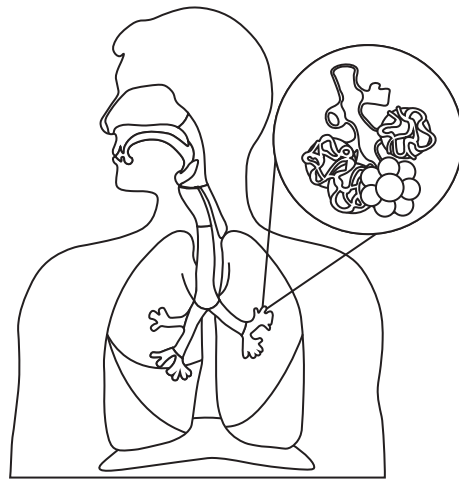
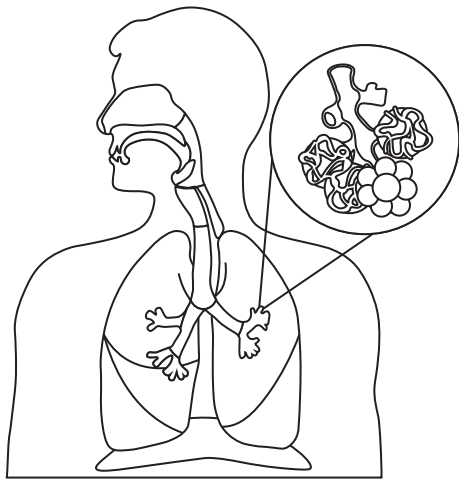
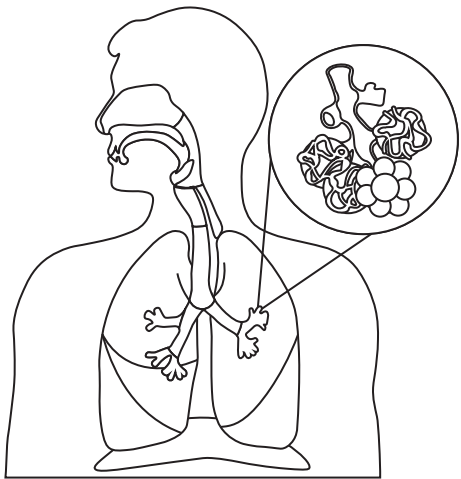
Left Lung (2 lobes)

Esophagus

Epiglottis

Diaphragm

Right Lung (3 lobes)



Capillary

Respiratory Bronchiole

Inferior Lobe

Alveolus

Superior Lobe

Alveolar Sac (Alveoli)

Middle Lobe