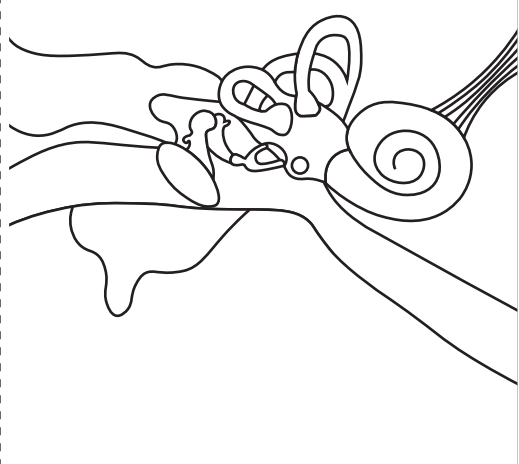
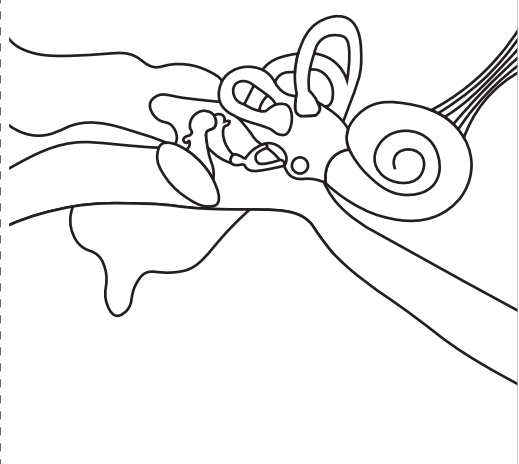
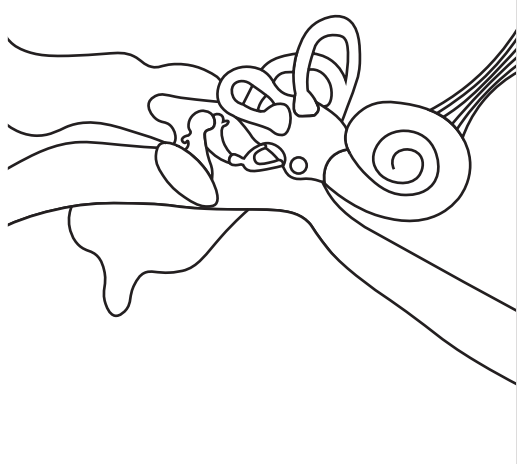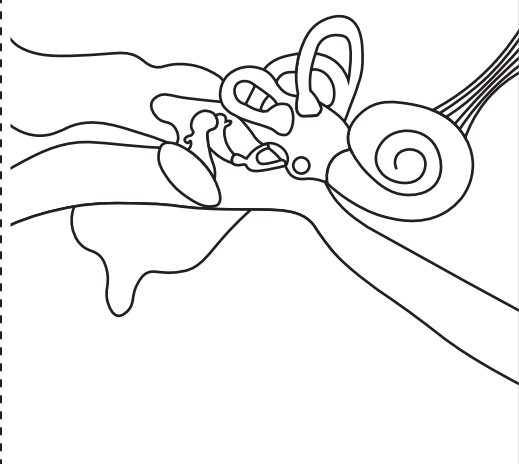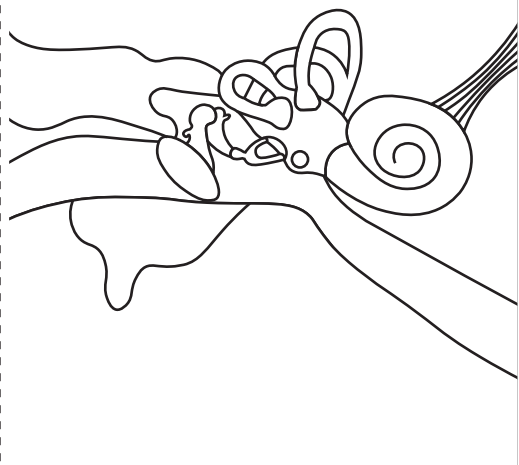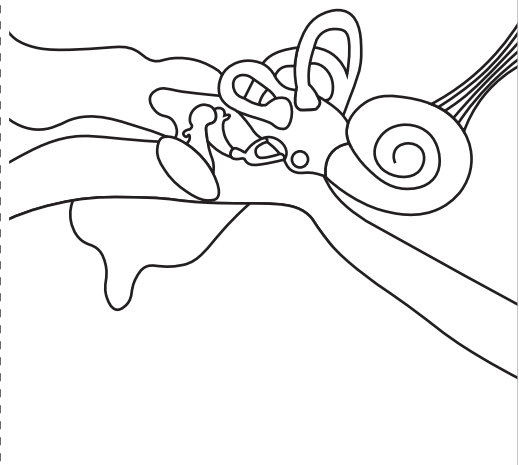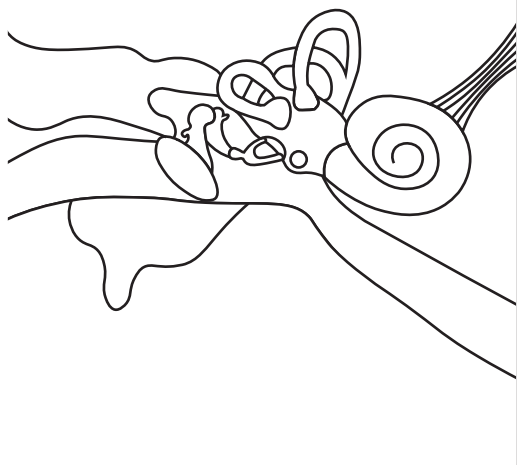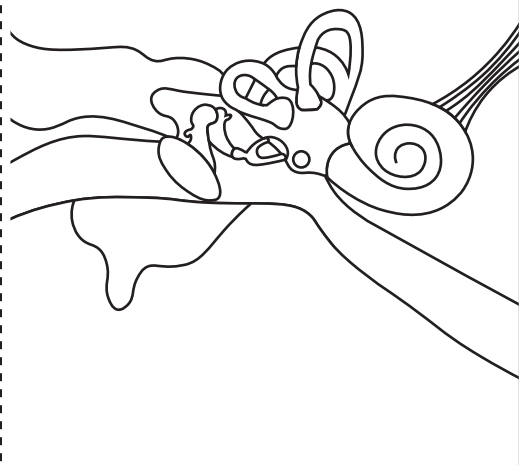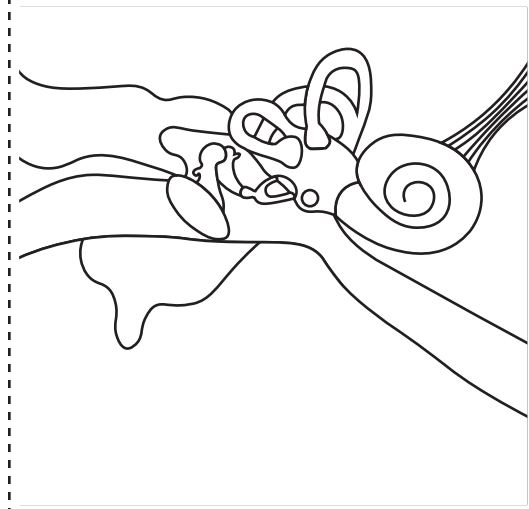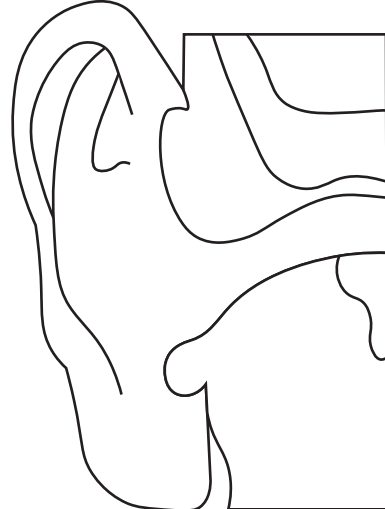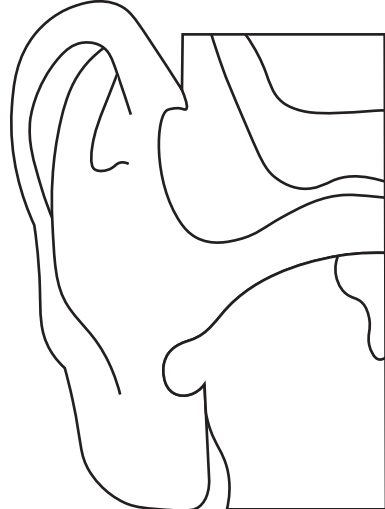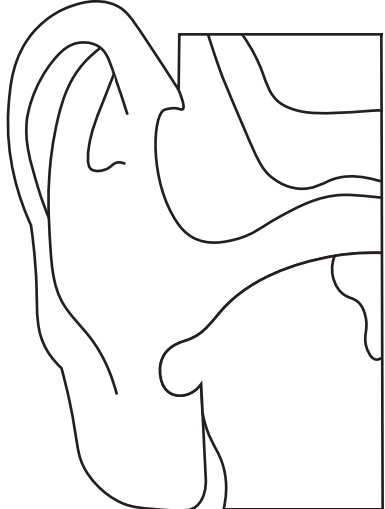Outer Ear

Auditory Canal

Ossicles

Incus

Semicircular Canals

Oval Window

Auditory/Eustachian Tube








Pinna

Tympanic Membrane

Malleus

Staples

Cochlea



Vestibular Cochlear Nerve 8

Round Window

Vestibule